

## Annotation

## What is a revision of total ankle replacement?

Anders Henricson MD PhD<sup>a,\*</sup>, Åke Carlsson MD PhD<sup>b</sup>, Urban Rydholm MD PhD<sup>c</sup><sup>a</sup> Dept Orthopedic Surg, Falu General Hospital, S-791 82 Falun, Sweden<sup>b</sup> Dept Orthopedic Surg, Malmö University Hospital, Lund University, Malmö, Sweden<sup>c</sup> Dept Orthopedic Surg, Lund University Hospital, Lund University, Lund, Sweden

## ARTICLE INFO

## Article history:

Received 27 January 2010

Accepted 12 February 2010

## Contents

1. Introduction . . . . .	99
2. Materials and methods . . . . .	99
3. Results . . . . .	99
4. Discussion . . . . .	100
References . . . . .	102

## 1. Introduction

The results of total ankle replacement (TAR) have improved during the last decade, but are still inferior to the results of hip and knee replacement. The complexity of the procedure depends on prosthetic design, instrumentation as well as indication and the experience of the surgeon and constitutes a great challenge for the foot and ankle surgeon. The long learning curve is well documented [1–3]. Deformity at, or below the ankle joint or in combination can be difficult to handle and are one of the main reasons for failure [4–7]. Altogether the procedure of total ankle replacement results in a substantial number of secondary procedures that may be named “revisions”, “reoperations” or “additional procedures”. In the literature there is no explicit definition of either of these procedures. In order to compare follow-up studies or survival rates it is crucial that different authors use the same definition.

## 2. Materials and methods

We searched for studies that were full length journal articles with a definition, even if vague, of revision of TAR. Only articles

concerning modern uncemented two component designs and uncemented three component designs were eligible.

A literature search was carried out in November 2009 using the following databases:

1. MEDLINE (PubMed) using the MeSH terms (ankle OR ankle joint) AND (replacement and arthroplasty). The term ankle prosthesis is not applicable on MEDLINE.
2. Cochrane Database of Systemic Reviews (ankle AND replacement OR arthroplasty OR prosthesis).
3. Cochrane Central Register of Controlled Trials (ankle AND replacement OR arthroplasty OR prosthesis).
4. Google Scholar (exact phrase in title: ankle replacement, ankle arthroplasty or ankle prosthesis).
5. The journal Foot and Ankle Surgery (ankle replacement, ankle arthroplasty or ankle prosthesis).

## 3. Results

Twenty-four full length journal articles met the criteria and were included in the study. The flow chart is presented in Fig. 1. The different concepts used to calculate revision rates and survival curves by various authors are summarized in Table 1. These concepts concern procedures involving the prosthetic components

\* Corresponding author. Tel.: +46 23492478; fax: +46 23492093.  
E-mail address: [anders.henricson@tdalarna.se](mailto:anders.henricson@tdalarna.se) (A. Henricson).

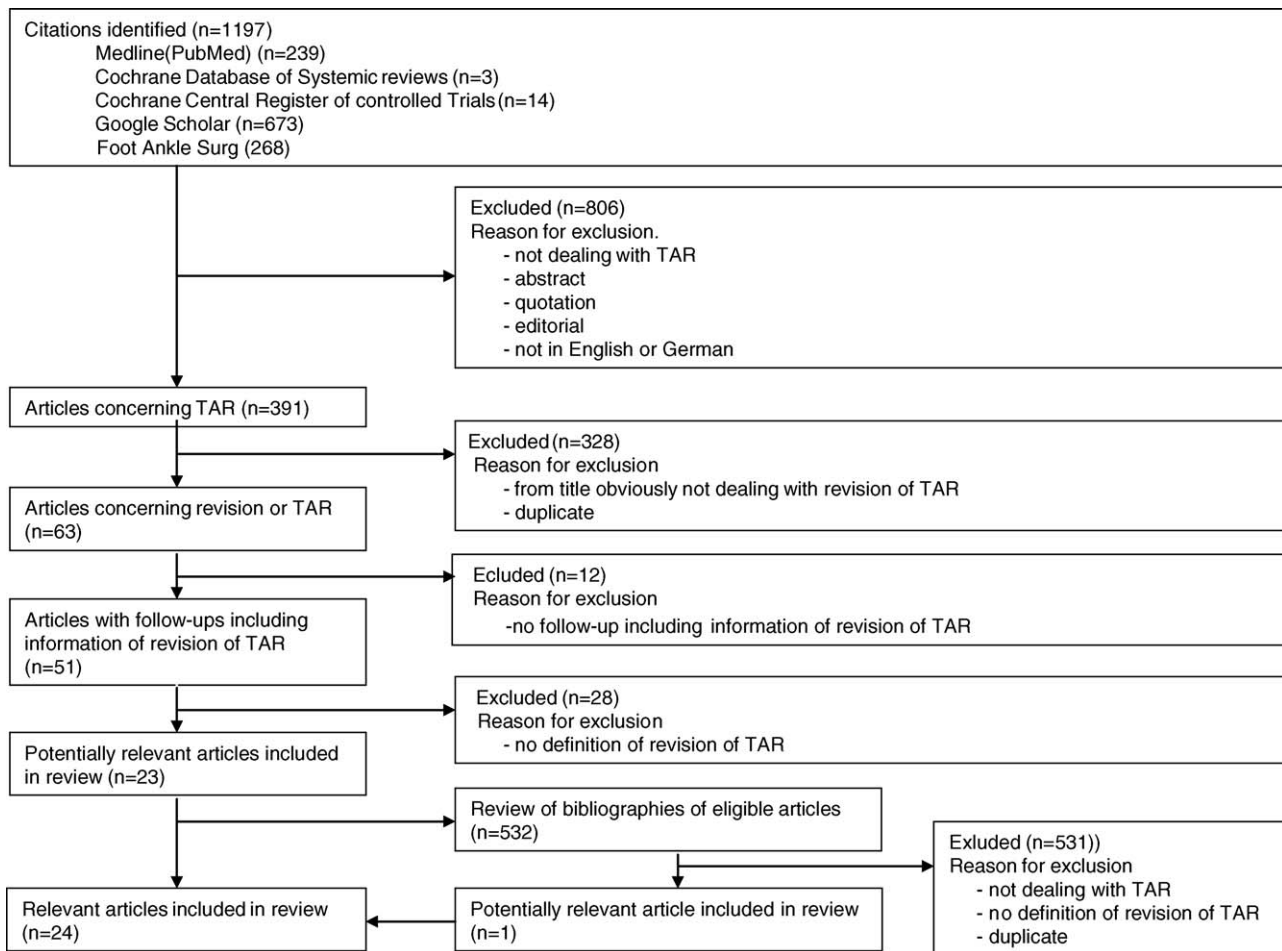


Fig. 1. Flow diagram of included studies.

exclusively. Anderson et al. [8] and Carlsson [1] used *revision for any reason* in their articles, but when scrutinizing their studies it is obvious that this concept includes removal or exchange of one or more of the metallic components or exchange of the polyethylene meniscus in case of wear or fracture. *Failed total ankle arthroplasty* in the studies by Spirt et al. [9] and Hosman et al. [10] implies removal or replacement of components, arthrodesis or a below knee amputation.

Secondary surgery not concerning the prosthetic components was designated with different terms by different authors: *further surgery* [3,11], *subsequent surgery* [5,12], *corrective surgery* [7], *additional procedures* [13,14], *reoperations* [6,13], *minor secondary operations* [15] or *revision* [16].

#### 4. Discussion

The vast number of secondary procedures after TAR reflects the complexity of the concept [3,6,9,11–15,17]. The increasing number of follow-up reports and survival analyses necessitates distinct definitions when analysing and comparing different studies of TAR. One limitation of a review like this is the possibility to fail to identify some studies, but we believe that the search has been extensive and that this possibility is minute.

This study shows varying definitions of secondary surgery after TAR. Some authors use *revision* synonymous with exchange of components [3,5,7,11,18–22]. Most authors use a more global definition of *revision* including both exchange and removal of components [1,2,6,8,13–15,17,23,24]. Thus, there is obviously a strong need for plain definitions concerning the different

procedures of secondary surgery after TAR. An agreement to designate *revision* to secondary surgery involving the prosthetic components would clarify and simplify the interpretation and comparison of follow-up studies.

Removal of components, leading to arthrodesis or not, is thereby obviously a revision, which is clearly stated by most authors. Below-the-knee-amputation [9,10,17,25] as a consequence of frightful complications after TAR is by definition a removal of the prosthesis and should therefore be considered a revision.

Exchange of one or more of the metallic components for any reason is considered a revision by almost all authors. Bonnin et al. had no exchanges of components in their study [16], but use the term *revision* for secondary procedures like synovectomy and arthrolysis. Wood et al. describe a re-impaction of a tibial component 3 days after surgery as a result of a technical error but do not consider the procedure to be a revision [21].

There seems to be a strong concordance of considering removal or exchange of one or more metallic components as a revision of TAR.

Exchange of the polyethylene meniscus due to fracture or wear is considered a revision by several authors [1,2,8,13,20,21]. However, Knecht et al. [15] report on a polyethylene exchange due to polyethylene fracture and consider that operation to be a non-revision procedure. Fevang et al. [23] describe exchange of six polyethylene inserts as a sole procedure as revisions, though they only report two inserts with polyethylene wear.

The polyethylene meniscus could be exchanged for many reasons, the most obvious being fracture or wear. The insert might however also be exchanged due to instability and incidentally in

**Table 1**  
Concepts for revision used by different authors.

Concepts used in follow-up studies	Authors
Exchange or extraction of one or more components	Saltzman et al. [17] Knecht et al. [15] San Giovanni et al. [14] Fevang et al. [23] SooHoo et al. [24] Henricson et al. [2] Henricson and Ågren [6] Karantana et al. [12]
Revision <sup>a</sup> of the prosthesis or arthrodesis	Wood and Deakin [11] Kofoed [22] Doets et al. [5] Wood et al. [20] Wood et al. [7] Schutte and Louwerens [19] Wood et al. [21]
Implant revision <sup>a</sup> or revision <sup>a</sup>	Buechel et al. [18] Kumar and Dhar [3]
Implant removal	Bonnin et al. [16] van der Heide et al. [25]
Failed total ankle arthroplasty	Spirit et al. [9] Hosman et al. [10]
Extraction or exchange of one or both metallic components or exchange of the polyethylene meniscus due to fracture or wear	Anderson et al. [8] Carlsson [1] Henricson et al. [13]

<sup>a</sup> Revision in these contexts implies exchange of components.

**Table 2**  
Proposed definitions of secondary procedures.

Revision	Removal or exchange of one or more of the prosthetic components with the exception of incidental exchange of the polyethylene insert
Reoperation	Non-revisional secondary surgery involving the joint
Additional procedure	Non-revisional secondary surgery not involving the joint

secondary operations because of infection, impingement of the gutters or bony overgrowth.

In cases of instability the main reason is often malalignment left from the index procedure or gradually arising with time. Realignment of the joint with corrective osteotomies, ligament reconstruction and ligament transfers often require exchange of the polyethylene insert. Subsidence of the components is a common phenomenon in radiological follow-ups [5,14,15,18], and have also been demonstrated in a radiostereometric analysis (RSA) study [26]. The reason might be a too proximal tibial cut into the weak metaphyseal bone or a minor technical error with wrong inclination angles not detected immediately postoperatively. Subsidence can lead to instability or lowering of the malleoli onto the talar sides in the medial or lateral gutter which may need insertion of a higher polyethylene meniscus. Insertion of a primarily too thin meniscus is a technical error, also leading to instability and exchange of the polyethylene meniscus in these cases reflects the complexity of the surgery and should be considered as a revision.

Incidental exchange of the polyethylene insert can occur in secondary operations due to infection, impingement or bony overgrowth. Deep infection can sometimes be eradicated by washout, synovectomy and antibiotics [5,13,21] and the polyethylene insert has to be taken out in order to clean the joint properly. This should *not* be regarded as a revision, first of all because it is not related to the prosthetic concept as such. Secondly, if a surgeon choose to replace the same insert no exchange has been performed. The theoretical consequence might then be that the same procedure sometimes is a revision and sometimes not. The same

discussion is relevant when performing secondary procedures due to e.g. narrow gutters or bony overgrowth.

Glazebrook et al. classified complications in total ankle arthroplasty as high-grade, medium-grade and low-grade complications [27]. The probability of failure was greater than 50% in high-grade complications and less than 50% in medium-grade complications. The classification might be helpful as a guidance of postoperative care, when knowing how dangerous a specific complication can be. However, in medium-grade complications, e.g. there will still be a substantial and unknown number of failures leading to revision and the classification will thus not be useful when calculating revision rates or survival curves.

There are principally two kinds of secondary surgery not involving the prosthetic components. On one side procedures involving the joint, e.g. debridement, washout, incidental insert exchange and on the other side procedures not involving the joint, e.g. deltoid release, subtalar fusion, calcaneal osteotomy, ligament reconstruction, and Achilles tendon lengthening. In order to distinguish between those we propose the terms reoperation and additional procedures, respectively (Table 2). In conclusion we suggest that a revision of TAR is defined as removal or exchange of one or more of the prosthetic components with the exception of incidental exchange of the polyethylene insert.

#### Conflict of interest statement

None of the authors have received funding in relation to this study.

## References

- [1] Carlsson Å. Single- and double-coated STAR total ankle replacements. A clinical and radiographic follow-up study of 109 cases. *Orthopäde* 2006;35:527–32 [German].
- [2] Henricson A, Skoog A, Carlsson Å. The Swedish ankle arthroplasty register. An analysis of 531 arthroplasties between 1993 and 2005. *Acta Orthop* 2007;78:569–74.
- [3] Kumar A, Dhar S. Total ankle replacement: early results during learning period. *Foot Ankle Surg* 2007;13:19–23.
- [4] Haskell A, Mann R. Ankle arthroplasty with preoperative coronal plane deformity: short-term results. *Clin Orthop Relat Res* 2004;424:98–103.
- [5] Doets HC, Brand R, Nelissen RGH. Total ankle arthroplasty in inflammatory joint disease with use of two mobile-bearing designs. *J Bone Joint Surg Am* 2006;86:1272–84.
- [6] Henricson A, Ågren PH. Secondary surgery after total ankle replacement. The influence of preoperative hindfoot alignment. *Foot Ankle Surg* 2007;13:41–4.
- [7] Wood PLR, Prem H, Sutton C. Total ankle replacement. Medium-term results in 200 Scandinavian total ankle replacements. *J Bone Joint Surg Br* 2008;90:605–9.
- [8] Anderson T, Montgomery F, Carlsson Å. Uncemented STAR prostheses. Three to eight-year follow-up of fifty-one consecutive ankles. *J Bone Joint Surg Am* 2003;86:1321–9.
- [9] Spirt AA, Assal M, Hansen ST. Complications and failure after total ankle arthroplasty. *J Bone Joint Surg Am* 2004;86:1172–8.
- [10] Hosman HH, Mason RB, Hobbs T, Rothwell AG. A New Zealand national joint registry review of 202 total ankle replacements followed for up to 6 years. *Acta Orthop* 2007;78:584–91.
- [11] Wood PLR, Deakin S. Total ankle replacement. The results in 200 ankles. *J Bone Joint Surg Br* 2003;85:334–41.
- [12] Karantana A, Hobson S, Dhar S. The Scandinavian total ankle replacement: survivorship at 5 and 8 years comparable to other series. *Clin Orthop Relat Res*; in press, doi:10.1007/s11999-009-0971-y.
- [13] Henricson A, Knutson K, Lindahl J, Rydholm U. The AES total ankle replacement. A mid-term analysis of 93 cases. *Foot Ankle Surg* 2010;16:61–4.
- [14] San Giovanni TP, Keblish DJ, Thomas WH, Wilson MG, Gables C. Eight-year results of a minimally constrained total ankle arthroplasty. *Foot Ankle Int* 2006;6:418–26.
- [15] Knecht SI, Estin M, Callaghan JJ, Zimmerman MB, Alliman KJ, Alvine FG, et al. The Agility total ankle arthroplasty: seven to sixteen-year follow-up. *J Bone Joint Surg Am* 2004;86:1161–71.
- [16] Bonnin M, Judet T, Colombier JA, Buscayret F, Piriou P. Midterm results of the Salto total ankle prosthesis. *Clin Orthop Relat Res* 2004;424:6–18.
- [17] Saltzman CL, Amendola A, Anderson R, Coetzee JC. Surgeon training and complication in total ankle arthroplasty. *Foot Ankle Int* 2003;24:514–8.
- [18] Buechel Sr FF, Buechel Jr FF, Pappas MJ. Twenty-year evaluation of cementless mobile-bearing total ankle replacements. *Clin Orthop Relat Res* 2004;424:19–26.
- [19] Schutte BG, Louwerens JWK. Short-term results of our first 49 Scandinavian total ankle replacements (STAR). *Foot Ankle Int* 2008;29:124–7.
- [20] Wood PLR, Crawford LA, Suneja R, Kenyon A. Total ankle replacement for rheumatoid ankle arthritis. *Foot Ankle Clin* 2007;12:497–508.
- [21] Wood PLR, Sutton C, Mishra V, Suneja R. A randomised controlled trial of two mobile-bearing total ankle replacements. *J Bone Joint Surg Br* 2009;91:69–74.
- [22] Kofeod H. Scandinavian total ankle replacement (STAR). *Clin Orthop Relat Res* 2004;424:73–9.
- [23] Fevang BTS, Lie SA, Havelin LI, Brun JG, Skredderstuen A, Furnes O. 257 Ankle arthroplasties performed in Norway between 1994 and 2005. *Acta Orthop* 2007;78:575–83.
- [24] SooHoo NE, Zingmond DS, Ko CY. Comparison of reoperation rates following ankle arthrodesis and total ankle arthroplasty. *J Bone Joint Surg Am* 2007;89:2143–9.
- [25] van der Heide HJL, Schutte B, Louwerens JWK, van der Hoogen FHJ, de Waal Malefijt MC. Total ankle prostheses in rheumatoid arthropathy. *Acta Orthop* 2009;80:440–4.
- [26] Carlsson Å, Markusson P, Sundberg M. Radiostereometric analysis of the double-coated STAR total ankle prosthesis. A 3–5 year follow-up of 5 cases with rheumatoid arthritis and 5 cases with osteoarthritis. *Acta Orthop* 2005;76:573–9.
- [27] Glazebrook MA, Arsenault K, Dunbar M. Evidence-based classification of complications in total ankle arthroplasty. *Foot Ankle Int* 2009;30:945–9.